

HODGKIN DISEASE IN CHILDREN : BICENTRIC STUDY

Andrianjafitrimo HT*, Randriarimanana OR*, Rasoarisoa E*, Ranaivomanana
VF**, Ramiandrasoa LA2**, Randrianjafisamindrakotroka NS** :

*SALFA Andohalo, University Hospital of Ravoahangy Andrianavalona, Pathology Departement,

*Corresponding Author:

Abstract

Hodgkin disease is a rare tumor within the pediatric population, exhibiting a higher incidence in developing countries such as Madagascar. The objective of this study was to elucidate the epidemiological and anatomopathological characteristics of Hodgkin's disease in the pediatric population of Madagascar.

A retrospective analysis was conducted, focusing on the description of Hodgkin's lymphoma diagnosed in children aged 0 to 15 years over five year intervals, spanning from January to December 2018. The data were sourced from the Pathological Anatomy and Cytology laboratories of the CHU-JRA and SALFA Andohalo.

Through out the study period, a total of 32 cases of Hodgkin's lymphoma in children were identified, constituting 43.24% of the diagnosed lymphoma cases during this period. The age of the patients ranged from 3 to 15 years, with an average age of 9.28 years. A notable male predominance was observed, with a sex ratio of 2.2. In all cases, the location was cervical region. The histological subtype revealed a predominance of the sclero-nodular variant in 69% of cases.

Our findings indicate a relatively higher prevalence of Hodgkin's disease in our study compared to other developing countries. It affected younger children in more than half cases, with a male predominance.

Keywords: Children, Hodgkin lymphoma, Madagascar

INTRODUCTION

Hodgkin's disease is a hematological malignancy distinguished by the presence of Reed-Sternberg cells within a heterogeneous inflammatory cell environment. It is a rare condition in the pediatric age group [1]. Advances in care have led to significant progress in developed countries, resulting in the recovery of over 90% of patients. However, in developing countries, the lack of available resources hinders the replication of such advancements.

The purpose of this study was to determine the epidemiological and anatomopathological characteristics of Hodgkin's disease in the pediatric population at two anatomopathological diagnostic centers in Madagascar.

MATERIAL AND METHOD

This study constitutes a descriptive and retrospective analysis of diagnosed cases of Hodgkin Lymphoma in children aged 0 to 15 years. The investigation was conducted at the Pathological Anatomy and Cytology laboratories of CHU-JRA and SALFA Andohalo over a five-year period, spanning from January 2014 to December 2018. The key parameters examined in this study included ages, gender distribution, clinical information, and histological subtypes.

Histological specimens were meticulously reviewed, and the data were entered into Microsoft Excel 2010. Subsequently, the collected data were processed using Epi Info 7 for comprehensive analysis and interpretation.

RESULTS

Throughout the study period, a total of 74 cases of lymphoma in children were documented, with 32 cases specifically identified as Hodgkin Lymphoma, accounting for 43.24% of the total cases. The average age of our patients was 9.28 years, with a range between 3 and 15 years (see Figure 1). Notably, a distinct male predominance was observed, reflected in a sex ratio of 2.2.

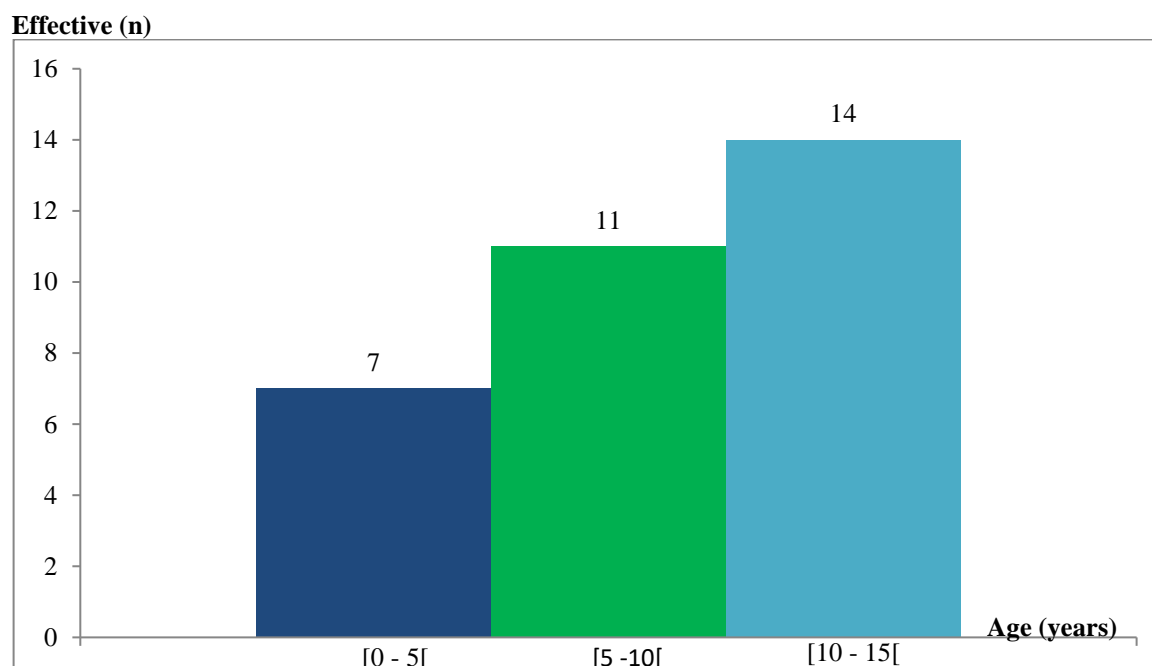


Figure 1 : Distribution according to age groups

Clinically, our patients presented with either unique adenopathy (13 cases) or multiple adenopathies (19 cases), and these were observed either in isolation (10 cases) or in association with other signs (9 cases). Notably, there were no instances of extra-nodal involvement. Associated signs included global manifestations in 5 patients, with 2 cases presenting anemia and 3 cases exhibiting tuberculous impregnation. Additionally, one patient displayed hepatosplenomegaly, while other notable findings included one case of abdominal mass, one case of mediastinal mass, and one case of lung mass.

All detected cases was on cervical site (100%).

Histologically, the sclero-nodular subtype was the most prevalent, accounting for 69% of cases (n=22). Mixed cellularity was observed in 19% of cases (n=6), while predominantly lymphocytic histological subtype constituted 12% of cases (n=4).

DISCUSSION

Hodgkin's disease is a clonal malignant hematological disorder distinguished by the presence of Reed-Sternberg cells within an inflammatory environment. While the occurrence of Hodgkin's disease in children is rare in developed

countries, it is markedly more frequent in developing nations, constituting over 10% of all childhood cancers [2]. Throughout our study period, we enrolled 32 patients, representing 43.24% of lymphoma cases in children. ISSN: 2208-2093

The epidemiological and clinical profile of Hodgkin's disease exhibits distinct characteristics in developing countries, often manifesting at an earlier age. In the thesis by EssisLorn JC, 51% of the patients were aged 6 to 10 years [3]. Similarly, Cavdar et al. In Turkey reported a 27% frequency of Hodgkin's disease in children under 6 years old [4]. Despite ongoing research, the etiology of Hodgkin lymphoma remains unknown. However, some factors are believed to play an etiological role. Early infection with the Epstein-Barr virus (EBV) appears to be a contributing factor.

Hodgkin cells have the capability to secrete numerous cytokines, which play a role in the pathogenesis of the disease and contribute to various symptoms. These cytokines include interleukins (IL) 1, 2, 5, 6, and 9, which are associated with lymphocytosis and eosinophilia, as well as transforming growth factor (TGF) contributing to sclerodermal fibrosis. Additionally, hematopoietic growth factors of the granular line (G-CSF, GM-CSF, and M-CSF) are implicated. These cytokines are potential contributors to the general symptoms of the disease, such as fever, weight loss, and night sweats [5].

The early onset of Hodgkin's disease poses a challenge in adapting treatments due to the heightened vulnerability of very young children. Our study aligns with findings in African literature, as 56.24% of our cases involved patients under 10 years old, with 21.87% under 6 years old.

Consistent with existing literature, our study and others demonstrate a male predominance, with this pattern being more pronounced in developing countries.

In our cases, the site of involvement was lymph node in the cervical region. EssisLorn JC [3], in his thesis, identified 35 cases with lymph node involvement and 10 cases with extra-lymph node involvement. The prevalence of cervical lymph node involvement is a common finding in the majority of literature series. This can be attributed to the accessibility of cervical lymph nodes and the fact that the presence of cervical swelling often prompts parents to seek medical consultation.

Anatomopathologically, the diagnosis of Hodgkin's disease is typically established through a lymph node biopsy. The predominant histological subtype varies by region. In Western countries, the sclero-nodular type prevails, accounting for over 60% of cases [7]. Conversely, in developing countries, type 3 (mixed cellularity) is more frequently observed, constituting 50 to 75% of all cases [8].

Interestingly, our series demonstrates a predominance of the sclero-nodular type, aligning more closely with the pattern observed in Western countries rather than the prevalent type in developing nations.

CONCLUSION

This study provides insights into the frequency and characteristics of Hodgkin's disease in Madagascar, highlighting its relatively common occurrence in developing countries. The predominant manifestation is often through cervical lymphadenopathy, affecting predominantly younger children, with 56% of our cases being under 10 years old. Notably, the histological subtype observed in our series aligns more with the pattern seen in Western countries, characterized by the prevalence of the sclero-nodular variant.

BIBLIOGRAPHY

1. Dorff W, Luders H et al. Preliminary results of the multicenter trial GPOH-HD 95 for the treatment of Hodgkin's disease in children and adolescents : analysis and outlook. *Klein Padiatr* 2003 ; 215(3) : 139 – 145
2. Parkin M, Nectoux J, Stiller C, Draper G. The incidence of childhood cancers worldwide. *Pediatrics* 1989 ; 44 :725-36
3. EssisLorn JC. Hodgkin's disease in black African children: epidemiological, clinical, paraclinical and evolving aspects (Experience of the clinical hematology department of Yopougon University Hospital). Thèse 2003.
4. Cadvar AO, Goozdasoglu S, Yavuz G, et al. Characteristics of « early type-I pattern » (0-6 years) Hodgkin's disease in Turkish children. *Turk J Haematol* 2002 ;19 :55-62.
5. Haluska FG, Brufsky AM et al. The cellular biology of the Reed-Sternberg cell. *Blood* 1994 ; 84 : 1005-19
6. Khanfir A, Toumi N et al. Hodgkin's disease in children in southern Tunisia: study of 23 cases; *Cancer/Radiotherapy* 11 (2007) 241 – 246
7. Shankar AG, Ashley S, Radford M, Barrett A, Wright D, Pinkerton CR. Does histology influence outcome in childhood Hodgkin's disease ? Results from United Kingdom Children's Cancer Study Group. *J Clin Oncol* 1997 ; 15 :2622-30
8. Alebouyeh M, Vossough P. Hodgkin disease in Iranian children. *Eur J Pediatr* 1993 ;152 :22 - 3