

THE ORBITAL MESENCHYMAL CHONDROSARCOMA: A RARE

**Andrianjafitrimo^{1*}, Ony Randrianjafisamindrakotroka², Rindra Rafanomezantsoa³,
Léa Raobela⁴, Nantenaina Soa Randrianjafisamindrakotroka⁵**

*^{*1,2,3,4,5}Training and Research Care Unit in Ophthalmology CHU-JRA Antananarivo. Madagascar
Faculty of Medicine of Antananarivo. Madagascar*

***Corresponding Author:**

ABSTRACT

Orbital mesenchymal chondrosarcoma is a rare malignancy. We report the case of a 15-year-old boy, whose presenting sign consisted of left exophthalmos. Computed tomography and brain MRI showed an infraorbital mass. Histological examination of the specimen concluded to a mesenchymal chondrosarcoma. The epidemiological and histological aspects are discussed

KEYWORDS: *chondrosarcoma, orbit, histology, malignant tumor*

INTRODUCTION

Chondrosarcoma is a very destructive malignant tumor of cartilaginous, bone and mesenchymal origin. The localization at the level of the head and the neck is rare and the retro-ocular seat is even more so. We report a case of orbital mesenchymal chondrosarcoma. The aim of our work is to show through this clinical case, the importance of the anatomopathological examination in the confirmation of the diagnosis.

OBSERVATION

This was a 16-year-old boy with rapidly progressive left proptosis (Figure 1) over a month with decreased vision. The clinical examination of the left eye showed a drop in visual acuity, amounting to 1/10 P3 slow; as well as a complete partial limitation of oculomotor movements, a non-inflammatory exophthalmos that is slightly reducible, non-pulsatile, non-blowing. Marcus Gunn's sign was present. Fundus examination revealed mild stasis papilledema. The right eye examination was normal. A cerebral scan showed a calcified left intra-orbital mass with rupture of the left lamina papyracea, of the roof of the orbit and widening of the optic canal, with intracranial extension on the left frontal lobe and the left temporal lobe (Figure 2). Magnetic resonance imaging revealed an intra-orbital and extra-ocular mass syndrome at the origin of the grade 2 exophthalmos. A biopsy was performed, the histological examination of which showed a tumoral proliferation made up of spindle-shaped cells with cytonuclear atypia moderate, organized in bundles elaborating a chondroid stroma, which was typical of a mesenchymal chondrosarcoma (Figure 3).

DISCUSSION

Orbital mesenchymal chondrosarcoma is an extremely rare malignancy. It is a primary malignant bone tumor producing tumor cartilage without ever developing tumor bone tissue [1]. It accounts for 10 to 20% of malignant bone tumors [1] and only 7% of chondrosarcomas involve the head and neck region [2].

The first case of chondrosarcoma was described in 1959 by Lichtenstein and Bernstein [3]. This tumor usually appears between the ages of 20 and 30, with a female predominance [4]. Our case was a 16-year-old boy, which shows the particularity of our study.

The preferred site remains the head and neck, the meninges (25%), the lower limbs (leg 20%, thigh 20%) [5]. Its location in the orbit is extremely rare; only 18 cases of primary orbital mesenchymal chondrosarcoma have been published in the literature up to 2004 [6].

Symptoms vary depending on the location and extension of the tumour. These may be ocular signs such as a decrease in visual acuity, visual fog, retro-orbital or poorly systematized headaches, endocrine signs due to compression of the pituitary stalk, rhinological signs: nasal obstruction, rhinorrhea especially unilateral [7]. Progressive exophthalmos and decreased visual acuity are the main symptoms revealing the lesion in our case.

Cerebral computed tomography shows a well-defined lesion with areas of lumpy or curvilinear calcifications, enhancing moderately after injection of the contrast product [6]. Magnetic resonance imaging is the key examination in management, making it possible to study the relationship between the tumor and the intra-orbital structures and to make the differential diagnosis with other intra-orbital masses [6].

Thus, the lobulated character and the presence of calcification with enhancement in the periphery is in favor of chondrosarcoma. CT scan and magnetic resonance imaging of our patient showed these specific signs.

The microscopic structure is characteristic when it brings together two components [5]: small, undifferentiated, round or spindle-shaped mesenchymal cells with hemangiopericytic features around dilated and branched vascular clefts and well-differentiated islands of cartilage, with frequent calcification or ossification. These islets can be very rare and must be sought with care (interest of good sampling). There is sometimes a marked inequality in the size and shape of the cartilage cells. Indeed, the ratio of cellular areas to cartilaginous areas is very variable, the transition between the two areas being sometimes clear, sometimes progressive in the same tumour. These histological features were observed in our patient, which confirmed the diagnosis of mesenchymal chondrosarcoma. However, the absence of cartilage can lead to other differential diagnoses, especially small round cell tumours: hemangiopericytoma, rhabdomyosarcoma, lymphoma, neuroblastoma. Immunohistochemical study is then the key examination which makes it possible to show frank and intense labelling by vimentin, whereas the positive desmin in rhabdomyosarcoma and the positive leukocyte common antigen (LCA) in lymphoma are negative [6].

The treatment of chondrosarcoma is surgical, although complete tumor excision can be done at the expense of significant aesthetic sequelae and quality of life [8], due to the extension to adjacent structures.

The prognosis for this tumor is poor. It depends on the tumor extension and the quality of the excision [9]. In our case, the patient was lost sight of.

CONCLUSION

Mesenchymal chondrosarcoma is a rare bone and extra-skeletal tumor. Its infraorbital localization is extremely rare. Its prognosis depends on the quality of care. Only oncological resection followed by local radiotherapy and appropriate chemotherapy guarantees a good prognosis.

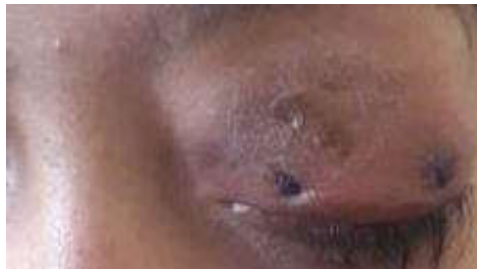

Figure 1: Left eye proptosis

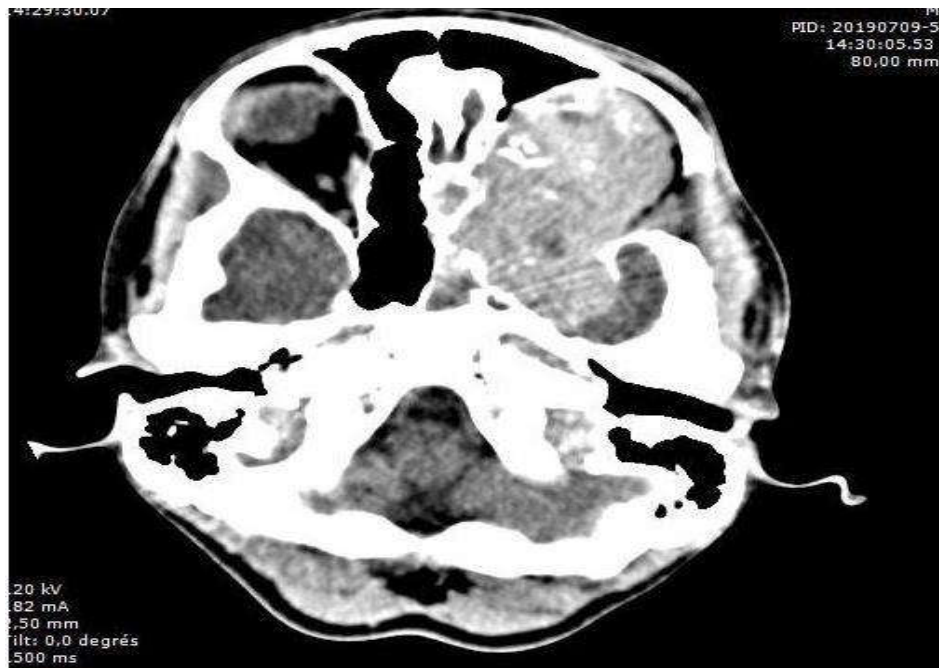

Figure 2: Brain scan showing an intraorbital mass

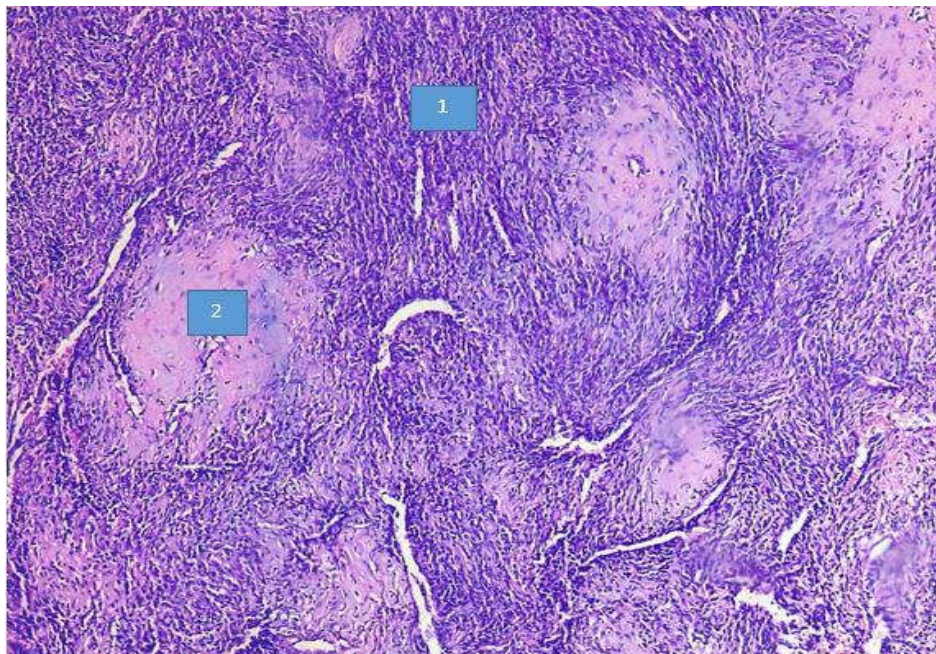


Figure 3: Intra-orbital tumour: mesenchymal chondrosarcoma

- Proliferation of small round or spindle-shaped cells
- Islands of well-differentiated cartilage

Magnification : HE x 20

Stain : Hématoxyline –éosine

Source : Paraclinical Unit for Training and Research in Pathological Anatomy and Cytology of the CHU Joseph Ravoahangy Andrianavalona

REFERENCES

- [1] Pontes H, Pontes F, de Abreu M, de Carvalho P, de Brito Kato A, Fonseca F, et al. Clinicopathological analysis of head and neck chondrosarcoma: three case reports and literature review. *Int J Oral Maxillofac Surg*. 2012; 41:203-10.
- [2] Khan F, Mari A, Afzal R. Sphenoidal intracranial chondrosarcoma. *J Coll Physicians Surg Pak*. 2014;24: S34-6.
- [3] Lichtenstein L, Bernstein D. Unusual benign and malignant chondroid
- [4] tumors of bone. A survey of some mesenchymal cartilage tumors and
- [5] malignant chondroblastic tumors, including a few multicentric ones, as
- [6] well as many atypical benign chondroblastomas and chondromyxoid
- [7] firomas. *Cancer*. 1959; 12:1142-1157.
- [8] Patel R, Mukherjee B. Mesenchymal chondrosarcoma of the orbit. *Orbit*
- [9] 2012 Apr;31(2):126-8.
- [10] Pradhan SV, Sayami G, Sharma MR. Intracranial mesenchymal chondrosarcoma. Case report and review of the literature. *Nepal J Neuroscience*, 2004;1:131-4.
- [11] Tuncer S, Kebudi R, Peksayar G, Demiryont M, Cizmeci O, Ayan I, et al. Congenital mesenchymal chondrosarcoma of the orbit. Case report and review of the literature. *Ophthalmology* 2004; 111:1016-22.
- [12] Khan M, Husain Q, Kanumuri V, Boghani Z, Patel C, Liu J, et al. Management of sinonasal chondrosarcoma: a systematic review of 161 patients. *Int Forum Allergy Rhinol*. 2013; 3:670-7.
- [13] Lloyd S, Devesa-Martinez P, Howard D, Lund V. Quality of life of patients undergoing surgical treatment of head and neck malignancy. *Clin Otolaryngol Allied Sci*. 2003; 28:524-32.
- [14] Evans H, Ayala A, Romsdahl M. Prognostic factors in chondrosarcoma of bone: a clinicopathologic analysis with emphasis on histologic grading. *Cancer*. 1977; 40:818-31.