

Ocular complications of severe vernal keratoconjunctivitis (VKS) in Nangarhar province Afghanistan

Assistant professor Dr. Ghulam Farooq Rahimi

Teaching assistant Dr. Ibrarullah Rahimi

Lecturers in Ophthalmology department of Nangrahar University Teaching Hospital

Abstract:

VKC is a potentially severe, chronic, allergic condition, causing bilateral recurrent inflammatory disorder of the conjunctiva and cornea. **The aim of** this study was to assess the ocular complications and visual loss among patients with severe vernal keratoconjunctivitis (VKS). **Material and Methods** 481 patients with VKC seen at Department of Ophthalmology Nangerhar university teaching hospital were the study group. This is a retrospective none – comparative observational study between 30/06/2018 and 30/06/2019. Visual acuity was measured with the standard Snellen chart and for children less than 5 years of age Kay pictures were used. Visual impairment was assessed by means of the world health organization criteria, for visual disabilities. Cases with severe VKC that developed ocular complications leading to blindness and severe visual impairment were analyzed. **At the Results** the majority of VKC patients were males (75.9%). A total of 76 (15.8%) patients (60 boys and 16 girls) had severe VKC. the ocular findings among 20 patients with severe VKC that led to blindness and severe visual impairment included keratoconus (7) steroid – induced cataract (5) central corneal scars (5) and steroid induced glaucoma (3) two of the keratoconus cases developed acute hydrops.

Key Words: Cataract, Glaucoma, Keratoconus, Visual impairment, vernal keratoconjunctivitis

Introduction

The eye is a frequent target of inflammation in both local and systemic allergic reactions. The vast majority of ocular allergy affects the conjunctiva. vernal keratoconjunctivitis (VKS) is a severe form ocular allergic conjunctivitis causing disturbance of normal activities at school or work due to severe itching, grittiness, foreign body sensation, difficulty in opening the eyelids, photophobia and copious mucous discharge (kosrirukongs et al. 2001).

VKC is a potentially severe, chronic, allergic condition, causing bilateral recurrent inflammatory disorder of the conjunctiva and cornea. Typically occurs in males before the age of 10 year in 80% of cases, it lasts 2 – 10 years, and it usually resolves during puberty. Males have an earlier presentation of symptoms than females and the male to female ratio decreases with age (bonini et al., 2004).

VKC is more prevalent in hot and dry areas (Mediterranean basin, the Middle East, Africa and the Indian subcontinent). It is relatively unusual in most of North America and Western Europe (Bremond – Gignac et al., 2008). Risk factors include age, underlying atopic predisposition, extent of allergen exposure and individual immune response to antigenic stimulation. There is a significant history of other atopic manifestations such as eczema or asthma in patients with VKC (Ajaiyeoba, 2003). A family history of atopy is found in these patients.

Three types of VKC are recognized. Limbal type (fine papillae with circumferential gelatinous Limbal type (fine papillae with circumferential gelatinous Limbal infiltration and Horner – Trantas dots); the palpebral type (giant papillae of > 1 mm in diameter on the superior tarsal conjunctiva) and a mixed type. These features leave no doubt as to the diagnosis of VKC. The reasons underlying the development of the various types of VKC in these patients are not understood (Kumar, 2009).

The main symptoms are itching; redness and foreign body sensation. Lacrimation; photophobia; Blepharospasm and pseudo-ptosis due to palpebral thickening are highly specific symptoms of VKC. These symptoms if not treated appropriately can persist for weeks (Leonardi and Secchi, 2003). Seasonal exacerbation is common, but patients may have symptoms year-round especially those living in subtropical or desert climates. More than 60% of patients have repeated recurrences all year round (seasonal variation) and this led to the widely accepted hypothesis that VKC is an immunologically mediated hypersensitivity reaction to environmental antigens (Leonardi , 2002).

The signs include papillary response of the conjunctiva, principally of the Limbus or upper tarsus; thick abundant and ropy mucus; Trantas dots and “cobblestone papillae”. Keratitis (which occurs in up to 50% of cases) (Iqbal et al, 2003) and shield ulcers are sight-threatening complication.

There is an association of Keratoconus in VKC patients (Totan et al., 2001). Other risks are of cataract and glaucoma due to the steroids. VKC may cause significant complications and leads to loss of vision (Bremond-Gignac et al., 2008; bonini et al., 2003).

Although several studies have been published on this disease. Only few dealt with the visual problems and ocular complications and visual loss among patients with severe VKC in Nangarhar province, Afghanistan.

Methodology:

This is a retrospective non-comparative observational study done in Department Of Ophthalmology Nangarhar University Teaching Hospital

The study was done between 30 June 2018 and 30 June 2019.

Four hundred and Eighty-one consecutive patients (481) with VKC were the study group during the study period. Inclusion criteria were recurrent bilateral symptomatic VKC with conjunctival giant papillae formation at the superior tarsus and / or Limbus as the hallmark of the disease and the presence of persistent and recurrent symptoms of conjunctivitis. A simple clinical score by Bonini et al., (2004) was used for disease severity classification. Patients were deemed to have severe VKC if they had persistent symptoms and signs (diffuse palpebral conjunctival edema; thickening with papillary hypertrophy giant papillary conjunctivitis and had Limbal infiltration of 180 or more). Cases with allergic conjunctivitis other than VKC were excluded from the study.

Data collected included best spectacle corrected visual acuity (BSCVA) to each eye using Snellen's projection chart for children under the age of 5 years' Kay pictures were used. The world health organization (WHO) criteria for visual disabilities were used to assess visual impairment. The WHO recommended definitions of visual impairment and blindness, where normal vision, mild visual impairment and blindness were defined as visual acuity (VA) of 6/6-6/18; 6/24/-6/60; < 3/60, respectively.

Best corrected visual acuity used was in the better eye.

Meibomet slitlamp bio-microscopy for anterior segment examination, +90 diptre volk lenses for fundal examination and Zeiss Goldman Application tonometry information were retrieved from the case notes. Case notes of patients with visual acuity (VA) 3/60 – 6 /60 in the better eye (severe visual impairment) or < 3 /60 (blind) were selected for more extensive chart review to establish the main cause of severe visual impairment or blindness.

Descriptive analysis was performed on the data collected using Microsoft excels spreadsheet 2018.

Findings:

The majority of VKC patients (n = 481) were males (n = 365) and females (n=116) with a male: female ratio 3.1:1. Table 1 shows the age distribution of the patients with VKC. Gender distribution, clinical forms and age of onset are shown in table 2 all cases had bilateral disease.

A total of 76 (15,8%) patients (60 boys and 16 girls) had severe VKC fig . 1 show the visual acuity among the 76 patients and severe VKC. Visual loss among 20 patients with blindness and sever visual impairment included keraoconus (7), steroid – induced glaucoma (3) (Fig 2) . keratoconus was progressive in many patients, resulting in visual loss, often not correctable with glasses or contact lenses. Two of the keratoconus cases developed acute hydrops.

Discussion:

Allergic eye disease including vernal keratoconjunctivitis (VKC) are common disease in Afghanistan especially in area that have hot weather like Nangarhar province Jalalabad, VKC was identified as the most common conjunctival disease in children seen in hospital (ukponmwan, 2003). A study was done by Farouk et al (2005) in Kuwait university hospital in Sana'a. Yemen showed that allergic eye diseases are the second most common diagnosis in the eye clinics after refractive errors.

Majority of cases with VKC examined in this study were younger than 10 year. (49.2%) while still the disease persists to the adult age in a number of patients after the age of 20 years (1,9%).

Majority of cases were males (75, 9%) with male to female ratio of 3, 1:1 and that is similar to studies from Italy and Thailand (Lambiase et al., 2009; leonardi et al., 2006; kosrirukvongs et al., 2003).

Table 1: Age distribution of 431 vernal keratoconjunctivitis patients in Nangarhar University Teaching Hospital study.

Age (years)	Male	Female	Total
0 – 4	30	10	40
5 – 9	137	52	189
10 – 14	116	36	152
15 – 19	62	13	75
> 20	10	5	15
Total	365	116	481

Table 2: Details of 431 vernal keratoconjunctivitis patients in Nangarhar University Teaching Hospital study.

	Total (%)	Palpebral form (%)	Limbal form (%)	Mixed form (%)	Age at onset (years)
Male	365 (75.8)	143(29.7)	162(33.00)	60(12.40)	6.5 ± 5 (1-24)
Female	116(24.2)	21(4.3)	68(14.00)	27(5.6)	7.5±5 (1-25)
Total	481(100)	164(35.00)	230(47.00)	86(18.00)	7.0± 5 (1-25)

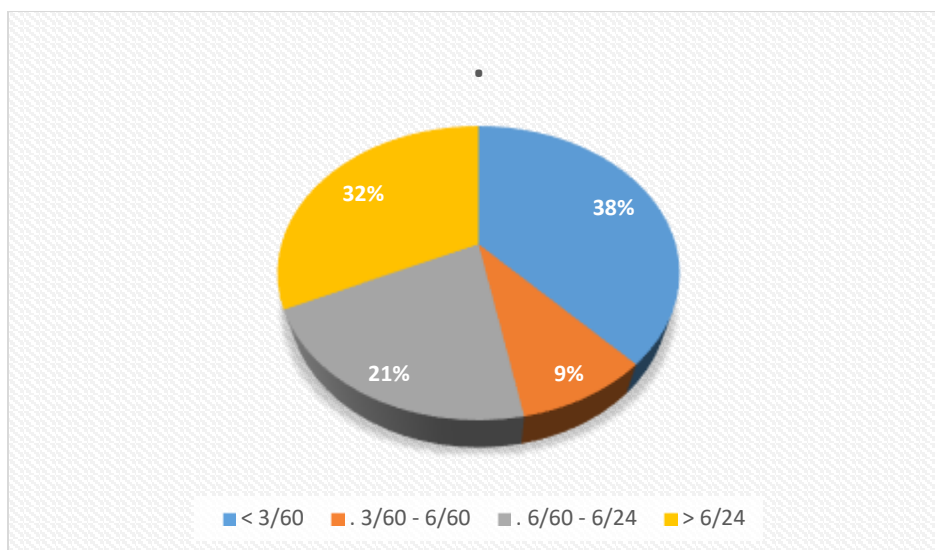


Figure 1: Visual acuity in the 76 patients with severe vernal kerato conjunctivitis.

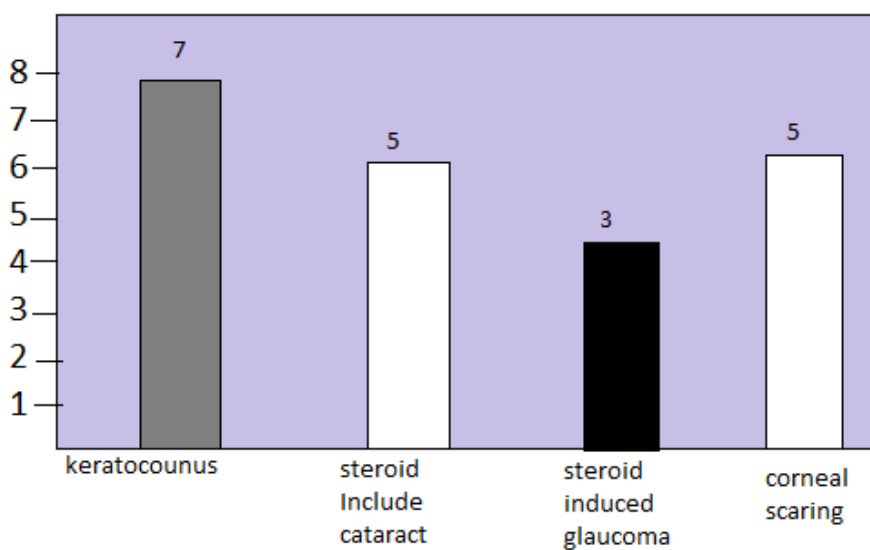


Figure 2: causes of poor vision in patients with severe vernal keratoconjunctivitis (20) patients.

Diagnosis of VKC was based on the patient's history and the presence of typical clinical signs and symptoms. The most common clinical type of VKC in this study was the Limbal type followed by the palpebral type and is the same as reported in other studies (Lambiase et al., 2009; Kosirukongs et al., 2003).

Fortunately majority of cases have the mild and moderate form of VKC. Severe VKC accounted for 15, 7% of the studied group and that is slightly more than the case series published by Lenardi et al. (2006) (7,8%) and Lambiase et al. (2009) (10%).

The ocular complication leading to blindness and severe visual impairment affected 20 patients (4,6%) and that is similar compared to studies (Bremond-Gognac et al., 2008) in a study by Tabbara in Saudi Arabia (Tabbara, 1999), 21% had a BSCVA of 20/200 or less due to steroid – induced cataract, steroid induced glaucoma, central corneal scars, irregular astigmatism and keratoconus.

Therapy for mild VKC includes preservative-free artificial tears, cold compresses and antihistamines. Treatment in severe cases of VKC is still problematic due to frequent exacerbations. Topical corticosteroids are usually given only for a short period of time to avoid the risk of side effects including glaucoma, cataract and infection (Kumar, 2009). Unfortunately, patients and their relatives keep seeing more than one doctor looking for cure from the disease and this leads to the prolonged unsupervised use of steroid drops and increasing the risk of complications.

Cyclosporine drops have good effect in VKC cases with fewer side effects (Gupta and Sahu, 2001) compared to corticosteroid. A close ophthalmological supervision with controlled discontinuous treatment according the disease severity is essential to avoid self-prescription and misuse of steroid drops.

Limitations of this study are: there were no immunological diagnostic tests done to this type of group patients because of limitations in the facilities available in Afghanistan. History of other associated allergic diseases and family history of allergic disease were not documented in this study. Also patients were not grouped to those who come from desert areas or the mountains to study the differences in presentations and ocular complication.

Conclusion:

VKC is not a rare disease in Afghanistan, and the severe form of VKC is a potentially blinding disease and carries significant societal costs. There is a need to a disease severity grading in order to develop standardized therapeutic guidelines based on the stage of VKC. Visual loss may be due to keratoconus and corneal scars, as well as complications of the unsupervised use of topically administered steroids.

Suggestions and recommendations:

- 1 We suggest to people whom suffer from VKC to avoid from excessive using of steroid without consultation of ophthalmologist
- 2 we offer to people whom annoy from VKC to use sun glasses; heat cap ‘washing eye with cold water and if they have facilities can change place of live from hot place to cold place.

References:

1. Boniini, S., Lamiase, A., Sgrutela, R., Bonini, S. (2003). Allergic chronic inflammation of the ocular surface in vernal keratoconjunctivitis. *Curr. open allergy clin. immunol.* 3(5), 381-387.
2. Bonini, S; Coassin, M, Aronni, S; Lambiase, A. (2004) vernal keratoconjunctivitis eye, 18,345-351.
3. Bremond Gignac, D. Donadieu, A; Leonardi, A; Pouliquen, P, Doan, S, Chiambaretta, F, et al, 2008. Prevalence of vernal keratoconjunctivitis: A rare disease? *Br. J. Ophthalmol.* 92, 1097-1102.
4. Farouk, S, Al-Tal, A., Bamashmus, M, Haider, T., (2005). prevalence of allergic eye diseases in Kuwait university Hospital, Sana'a, Yemen. Presented in the first Yemeni-Saudi conference of clinical immunology, Sana'a, May 25 – 26, 2005.
5. Gupta, V., Sahu, P.K, (2001). Topical Cyclosporine A in the Management of Vernal keratoconjunctivitis eye, 15, 39 – 41.
6. Iqbal, A., Jan, S., Babar, TF; Khan, M.D. (2003) Corneal Complication of Vernal Catarrh. *J. coll. Physicians surg.pak.* 13(7) , 394-397.
7. Kosrirukvongs, P, Visitsunthorn, N., Vichyanond, P., Bunnag, C. (2001). Allergic conjunctivitis. *Asian Pac. J. allergy Immunol.* 19, 237 – 244.
8. Kosrirukongs P., Vichyanond, Wongsawad, W., (2003) vernal keratoconjunctivitis in Thailand . *Asian Pac. J. Allergy immunol.* 21, 25 – 30.
9. Kumar, S. (2009). vernal keratoconjunctivitis : a major review. *Acta ophthalmol. Scand.* 87, 133 – 147.
10. Lambiase, A; Minchiotti S; Leonardi, A; Secchi, AG; Rolando M; Calabria, G, et al, (2009) . Prospective, multicenter demographic and Epidemiological study on vernal keratoconjunctivitis: a Glimpse of ocular surface in Italian population. *Ophthalmic epidermal.* 16, 38 – 41.
11. Lenoardi, A. (2002). vernal keratoconjunctivitis : pathogenesis and treatment . *Prog . Ret eye res.* 21, 319 – 339.
12. Leonardi, A; Secchi, A.G. (2003) vernal keratoconjunctivitis. *Inter. Ophthalmol . Clin.* 43, 41 – 58.
13. Leonardi, A., Busca, F., Motterle, L., Cavarzeran, F., Frgona, I.A., Plebani, M., et al., (2006), case series of 406 vernal keratoconjunctivitis patients : a demographic and epidemiological study. *Acta ophthalmol . Scand .* 84,406-410.
14. Tabbara, K.F., (1999). Ocular complications of vernal keratoconjunctivitis. *Can. J. ophthalmol.* 34(2), 88 – 92.
15. Totan, Y., Hepsen, I.F., Cekic, O., Gundus, A., Aydin, E., (2001). Incidence of keratoconus in subjects with vernal keratoconjunctivitis: a videokeratographic study. *Phthamology* 108,824-827.
16. Ukponmwan, C.U., (2003). Vernal keratoconjunctivitis in Nigerians: 109 consecutive cases. *Trop. Doct.* 33,242 – 245.